55th International Congress
SIDO 2024
17-19 October 2024
Florence
BUILDING BRIDGES
SIDO Società Italiana di Ortodonzia
174
Ute Schneider-Moser

# ORTHODONTIC MANAGEMENT OF THE OCCLUSAL PLANE FOR AN IDEAL SURGICAL CORRECTION OF THE MANDIBULAR ASYMMETRIES

Authors: M. Lombardo[1], F. Bitonto[1], E. Lipani[1], M. Verrone[1], E. Spinas[1]
[1]Department of Surgical Sciences, Postgraduate School of Orthodontics, University of Cagliari

## 1st Case



Orthodontic treatment



Pre-surgical orthodontic



**ORTHOGNATIC SURGERY**

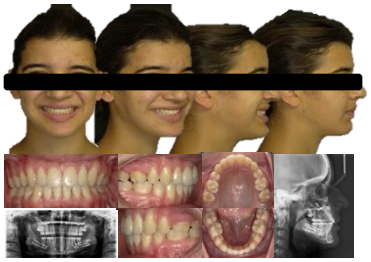

**Aim**
The aim of the poster is to show how the proper preparation of the maxillary and mandibular occlusal plane is mandatory to achieve the correction of facial asymmetries by means of the orthognathic surgery.

**Clinical case**
Two case reports are shown treated with straight wire Roth's appliance. The **first patient** is a 20-year-old woman who suffered of a **condylar hyperplasia** on the right side treated with condylar reshaping at 17 years old; she presented **severe mandibular asymmetry** and the remaining occlusal **open- bite on the side** of the hyperplasia.The **second case** is a 36-year-old woman whose request was to correct the **anterior open bite and mandibular asymmetries**

**Materials and Methods**
Both the patients were orthodontically prepared by Dr. Massimiliano Lombardo in his private practice before the orthognathic surgery done by Prof. Lorenzo Trevisiol, maxillofacial surgeon at the hospital of Verona.
The **orthodontic treatment** was carried out using a fixed Straightwire Roth's appliance and consisted in

- **1st case**: extraction of teeth #15 #25 #35 #45 for incisors proclination with crowding,
- **2nd case**: extraction of teeth #15 #25 for upper incisors proclination and crowding, corticotomy in the lower anterior sextant to allow proclination of the incisors preserving the buccal cortical bone from recessions

**Pre-surgical orthodontics** focused in the both cases on **decompensating the over- extrusion of molars and premolars** on the side where the mandibular ramus were bigger, creating an open- bite to facilitate surgical correction by giving space for the lateral shift of the mandible

**Surgery** consisted, in the first patient in **LeFort I** advancement and transvers correction of the maxilla and mandibular counter- clockwise rotation and facial midline correction; in the second case Le Fort I advancement and impaction with Y- cut on the anterior premaxilla and mandibular **counter-clockwise rotation with facial midline correction**.

**Results and Conclusions**
Both case reports achieved successful correction of mandibular asymmetry in difficult cases of hyperdivergent Class III patients. **Orthodontic decompensation of the skeletal asymmetry** created the necessary occlusal space for effective surgical correction. **Proper occlusal plane** orthodontic management is crucial for effective surgical correction of mandibular asymmetries in adult patients.

## 2nd Case



Orthodontic treatment

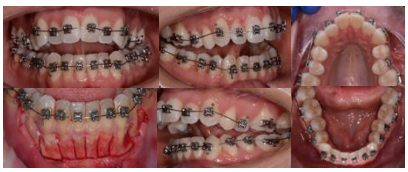

Pre-surgical orthodontic

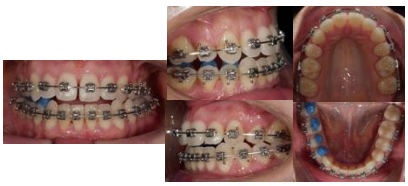

**ORTHOGNATIC SURGERY**



References:
- Mora Hurtado R, Ruiz Díaz R, Lucio Leonel E. Facial asymmetry correction with surgical-orthodontic treatment. Case report. Revista Mexicana de Ortodoncia [Internet]. 2016;4:e123–31.
- La Rosa S, Leonardi R, Ronsivalle V, Cicciù M, Lo Giudice A. Radiographic and diagnostic approaches for mandibular asymmetries in orthodontic practice: a narrative review. J Clin Pediatr Dent. 2024 Jul;48(4):1-15. doi: 10.22514/jocpd.2024.073. Epub 2024 Jul 3. PMID: 39087209.
- Grippaudo MM, Quinzi V, Manai A, Paolantonio EG, Valente F, La Torre G, Marzo G. Orthodontic treatment need and timing: Assessment of evolutive malocclusion conditions and associated risk factors. Eur J Paediatr Dent. 2020 Sep;21(3):203-208. doi: 10.23804/ejpd.2020.21.03.09. PMID: 32893653.
- Hanson PR, Melugin MB. Surgical/Orthodontic Treatment of Mandibular Asymmetries. Seminars in Orthodontics [Internet]. 2009;15:268–78.